



Laparoscopic management of 269 benign adnexal masses: A 6 year experience

Neelima T^{1*} and Surbhi Rathore¹

¹Department of Obstetrics and Gynaecology, Krishna Institute of Medical Sciences, Minister Road, Secunderabad-500003, Telangana, India

Abstract

Background: Benign ovarian pathology remains as a significant disorder in the female population of reproductive age group. During the last decades, laparoscopy has become the gold standard treatment of benign adnexal masses. Less adhesions, less operative pain and better cosmetic results are the advantages of this procedure. The objective of the study is to establish the role of laparoscopy in the management of benign adnexal masses. **Methodology:** The study included 269 patients with benign adnexal masses, treated laparoscopically in the Department of Obstetrics and Gynaecology, KIMS Hospital, Secunderabad from 2008 to 2015. **Results:** The diagnosis in 21 cases was endometriosis of the ovary (7.8%), in 26 cases it was hydrosalpinx (9.6%), in 42 cases serous cystadenoma (15.6%), in 80 cases dermoid (29.7%), in 9 cases para-ovarian tumors (3.3%), in 15 cases unruptured follicular cyst (5.6%), in 12 cases adnexal mass with uterine pathology (4.5%), in 7 cases ovarian torsion (2.6%), in 2 cases pregnancy with hydrosalpinx with torsion (0.7%), in 8 cases mucinous cystadenoma (3%), in 2 cases ovarian fibroma (0.7%), in 1 case Brenners tumor (0.37%), and in 44 cases ectopic pregnancy (16.4%). In 3 cases laparoscopy was converted to laparotomy due to technical difficulty. In 5 cases, frozen section was sent intra-operatively in view of suspicion of malignancy. **Conclusion:** Laparoscopy for the management of adnexal mass has the advantages of lower morbidity, shorter length of stay in hospital, decreased post-operative pain, lesser de-novo adhesion formations, better cosmetic results, faster recovery, and reduced overall cost of care. However, careful pre-operative evaluation is important for successful and appropriate use of laparoscopy for removal of adnexal masses.

Keywords: benign adnexal mass; females of reproductive age; laparoscopy; advantages of laparoscopy

***Corresponding author:** Dr. Neelima T., Krishna Institute of Medical Sciences, Minister Road, Secunderabad-500003, Telangana, India. Mobile: 09849991345; Email: neelimakantht@gmail.com

Received 16 December 2015; Revised 17 February 2016; Accepted 10 March 2016; Published 19 March 2016

Citation: Neelima T, Rathore S. Laparoscopic management of 269 benign adnexal masses: A 6 year experience. J Med Sci Res. 2016; 4(2):51-54. DOI: <http://dx.doi.org/10.17727/JMSR.2016/4-013>

Copyright: © 2016 Neelima T, et al. Published by KIMS Foundation and Research Centre. This is an open-access article distributed under the terms of the Creative Commons Attribution License, which permits unrestricted use, distribution and reproduction in any medium, provided the original author and source are credited.

Introduction

Benign ovarian pathology remains as a significant disorder in females of reproductive age group [1, 2]. Various types of adnexal masses are enlisted in Table 1 [3].

During the last decade laparoscopy has become the gold standard for the treatment of benign adnexal masses. Less adhesions, less operative pain and better cosmetic results are the advantages of this procedure [4]. However it remains controversial to decide in which cases, laparoscopy is indicated.

Table 1: Types of adnexal masses.

<i>Ovary</i>	Functional cyst Endometriotic cyst Neoplasms Ectopic pregnancy
<i>Fallopian tube</i>	Tubo-ovarian abscess Para-ovarian cyst Neoplasms Hydrosalpinx Ectopic pregnancy Tuberculous salpingitis

Possibility of malignancy should be excluded pre-operatively by history, physical examination and ultrasonography of ovarian cyst. Ultrasonography findings of benign and suspicious malignant masses are given in Table 2 [5]. Along with ultrasound, other pre-operative investigations for ruling out malignancy are given in Table 3.

Table 2: Ultrasonography findings of benign and suspicious malignant adnexal masses.

	<i>Benign</i>	<i>Suspicious</i>
Size	≤5cm	>10cm
Septal thickness	≤3mm	>3mm
Cyst wall thickness	≤3mm	>3mm
Papillary excrescences height	≤3mm	>3mm
Solid component	Absent	Present
Free fluid	Absent	Present
Doppler PI	>0.42	<0.42
Doppler RI	>1	<1

Table 3: Investigations to rule out malignancy.

<i>Diagnostic tool</i>	<i>Sensitivity (%)</i>	<i>Specificity (%)</i>
Bimanual examination	45	90
MRI	91	87
CT scan	90	75
CA-125 >35	78	78

Materials and methods

The study, laparoscopic management of adnexal masses, is a prospective observational study done from 2008 to 2015 in the Department of Obstetrics and Gynaecology, KIMS hospital, Secunderabad,

India. The cases included in this study are all patients planned for laparoscopic management of adnexal mass due to various indications.

Patients included in this study are females of more than 16 years of age with benign adnexal masses, and patients suspicious of ovarian malignancy are also included in this study, who were willing to be a part of this study.

Patients not willing for laparoscopy, patients diagnosed with malignancy pre-operatively, and patients not willing to be a part of this study are excluded from this study. All the patients were well informed about the study in all aspects and written consents were obtained. Variables studied in this study are given in Table 4.

Table 4: Variables studied in this study.

<i>Demographic data</i>	Age Previous abdominal surgeries
<i>USG findings</i>	Size of the mass Thickness of septa Number of papillary projections Presence of solid component
<i>Type of adnexal pathology</i>	Ovarian Fallopian tube Uterine pathology
Pre-operative haemoglobin	
Intra-operative laparoscopic findings	
Intra-operative difficulties encountered	
Intra- operative complications encountered	
Early post- operative complications	

Ultrasound is the imaging modality of choice in female pelvis. High resolution imaging of transvaginal ultrasound provides high diagnostic accuracy for pelvic pathology. However, there are some shortcomings with this modality, such as the limited field of view, obscuration of pelvic organs by the presence of bowel gas, inherent limitations depending on patient size, skill, and experience of the operator. When evaluating an adnexal mass on

ultrasound, the diagnostic challenges that may arise, include accuracy in localizing the mass, determining whether or not it is ovarian in origin; and when complex, whether it is definitely benign or malignant. If a cystic mass of >5cms in a premenopausal woman, or >3cm in postmenopausal woman is persisting or increasing in size on follow up ultrasound, MRI should be considered so that malignancy can be excluded. MRI should also be considered when a solid mass or a solid cystic adnexal lesion with internal color flow is detected by ultrasound. In these circumstances, it has been found that the use of MRI is cost effective as it reduces unnecessary surgical procedures.

Statistical analysis

After confirming the homogeneity of data, all variables will be expressed as mean \pm standard deviation. Categorical data will be expressed as percentage or frequency distribution charts. Association between variables will be analyzed using spearman correlation analysis and/or logistic regression analysis. All data analysis will be done using Statistical Package for Social Sciences (SPSS), version 17.0, IBM computers, and New York. $P \leq 0.05$ will be considered as significant.

Results

The study group consisted of 269 females, of more than 16 years of age. In all patients the diagnosis was made histologically. According to this result, 21(7.8%) patients were of endometriosis, 26(9.6%) patients were of hydrosalpinx, 42(15.6%) patients were of serous cystadenoma, 80(29.7%) patients were of dermoid, 44(16.4%) patients were of ectopic pregnancy, 9(3.3%) patients were of para-ovarian tumors, 15(5.6%) patients were of follicular cyst, 12(4.5%) patients were of adnexal mass with uterine pathology, 7(2.6%) patients were of ovarian torsion, 8(3%) patients were of mucinous cystadenoma, 2(0.7%) patients were of pregnancy with hydrosalpinx with torsion, 2(0.7%) patients were of fibroma, 1(0.37%) patient was of Brenner tumor.

In 3 patients laparoscopy was converted to laparotomy due to technical difficulties. In one case severe bowel adhesions were seen between uterus and ovaries which was a case of endometriosis. In second case, specimen was removed using mini-laparotomy incision, as the size of the specimen was

24cms. And the third case was found to have frozen pelvis for which diagnostic laparoscopy was done, and it was converted to laparotomy.

Figure 1 shows transvaginal scan of a 30-year-old patient who came with complaint of right lower abdominal pain showing dermoid tumor in right adnexa. Clustered punctuate high amplitude echo pattern created by hair in fat seen.

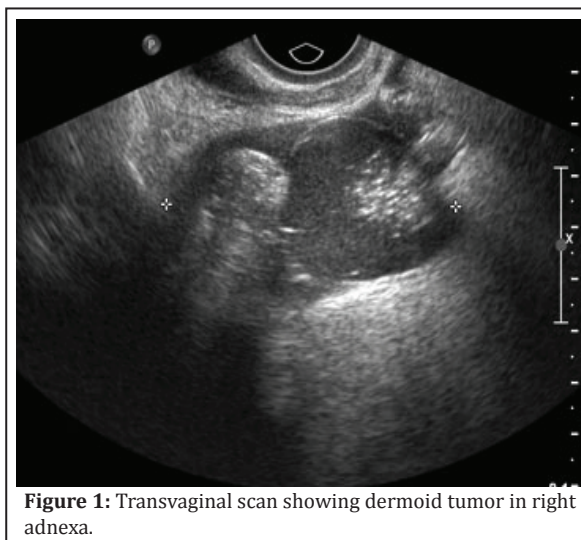


Figure 1: Transvaginal scan showing dermoid tumor in right adnexa.

In total 5 cases frozen sections were sent intra-operatively in view of suspicion of malignancy, and all 5 cases were found to be benign on frozen section.

Cysts were removed in plastic bag in all patients along with adnexal mass. A few complications were recorded like post-surgical fever, mild infection and pain at the suture site. The women were discharged normally two days after surgery. There was no major complication noted in any case.

Discussion

Benign ovarian masses are one of the most common issues which the gynaecologists have to treat. Laparotomy was considered to be the indicated treatment method until laparoscopic methods were developed. Since then continuous developments in methods of laparoscopy allowed it to be accepted as an alternative method to laparotomy, as it has additional advantages regarding patient's condition after surgery. Patients with big adnexal mass can be operated with laparoscopy, giving them the advantages of less post-operative pain and good cosmetic incision.

In this study a mass measuring 20cm was removed laparoscopically. It was a 20cm simple cyst in a young unmarried female, cyst was punctured and aspiration was done without any spillage, later cyst was removed using an endobag.

In cases of adnexal mass with uterine pathology, total laparoscopic hysterectomy was done along with adenectomy, and in these cases adnexal mass was removed vaginally.

A meta-analysis of related studies [6] comparing laparoscopy to laparotomy in the treatment of benign adnexal masses, point out the advantages of this procedure. It has been shown that laparoscopy caused less adverse effect, less post-operative pain, shorter stay in hospital, less readmission rates, better panoramic view, significantly low cost. Today it is almost accepted that laparoscopy is more beneficial than laparotomy but the importance of patient selection and the availability of gynaecologist should be taken into account. Potential malignant tumors should be carefully excluded from laparoscopic option. This is performed by use of combined transvaginal ultrasonography wherever possible with doppler and 3D ultrasound [7]. In that case parameters to be examined with attention are diameter of cyst larger than 5cm, existence of septae, solid particles of papillomatous structure. Regarding the tumor markers, CA-125 has a special predictive value. Ultrasound morphology is significantly more important than CA-125 in detecting malignancies. In large ovarian cysts (>10cm) transvaginal scans might not be able to visualise entire cyst contents, so transabdominal scan and MRI can yield better results [8].

Conclusion

Laparoscopy for the management of adnexal mass has the advantages of lower morbidity, shorter stay at hospital, decreased post-operative pain, lesser de-novo adhesions formation, better cosmetic result, faster recovery, and reduced overall cost of care. However, careful pre-operative evaluation is important for successful and appropriate use of laparoscopy for removal of adnexal masses and the advantages of laparoscopic approach, in no way, should compromise the clinical outcome in women with malignancy. Patient's age, history, findings of physical examination, and the results of serum

marker in combination with the imaging assessment, such as doppler sonography, MRI or CT, should be used to reach the correct diagnosis pre-operatively. Lastly, laparoscopy, as a successful treatment of any adnexal mass depends on surgeons' skill and experience.

Acknowledgement

The Departments of Obstetrics & Gynaecology, Radiology & Imageology, Krishna Institute of Medical Sciences, Secunderabad, India.

Conflicts of interest

There are no conflicts of interest and all the authors were in tone of study.

References

1. Westhoff C, Clark CJ. Benign ovarian cysts in England and Wales and in the United States. *Br J Obstet Gynaecol.* 1992; 99(4):329-332.
2. Hilger WS, Magrina JF, Magtibay PM. Laparoscopic management of the adnexal mass. *Clin Obstet Gynecol.* 2006; 49(3):535-548.
3. Givens V, Mitchell GE, Harraway-Smith C, Reddy A, Maness DL. Diagnosis and management of adnexal masses. *Am Fam Physician.* 2009; 80(8):815-820.
4. Canis M, Mage G, Pouly JL, Wattiez A, Manhes H, et al. Laparoscopic diagnosis of adnexal cystic masses: a 12-year experience with long-term follow-up. *Obstet Gynecol.* 1994; 83(5 Pt 1):707-712.
5. Van Nagell JR, Hoff JT. Transvaginal ultrasonography in ovarian cancer screening: current perspectives. *Int J Womens Health.* 2013; 6:25-33.
6. Medeiros LR, Stein AT, Fachel J, Garry R, Furness S. Laparoscopy versus laparotomy for benign ovarian tumor: a systematic review and meta-analysis. *Int J Gynecol Cancer.* 2008; 18(3):387-399.
7. Matsushita H, Watanabe K, Yokoi T, Wakatsuki A. Unexpected ovarian malignancy following laparoscopic excision of adnexal masses. *Hum Reprod.* 2014; 29(9):1912-1917.
8. Eltabbakh GH, Charboneau AM, Eltabbakh NG. Laparoscopic surgery for large benign ovarian cysts. *Gynecolo Oncol.* 2008; 108(1):72-76.