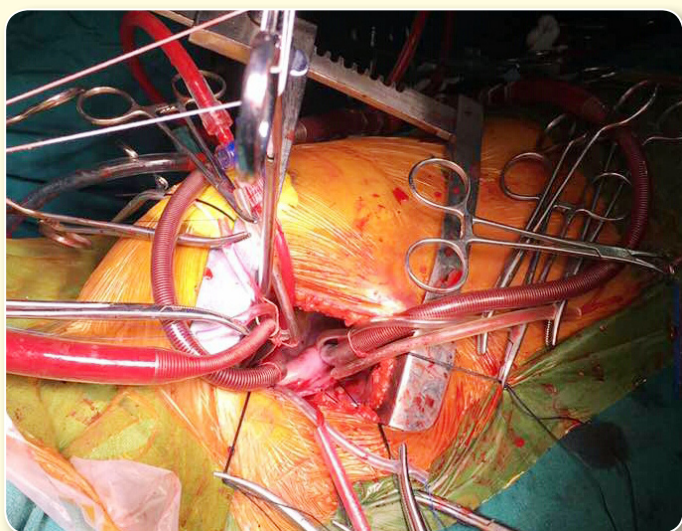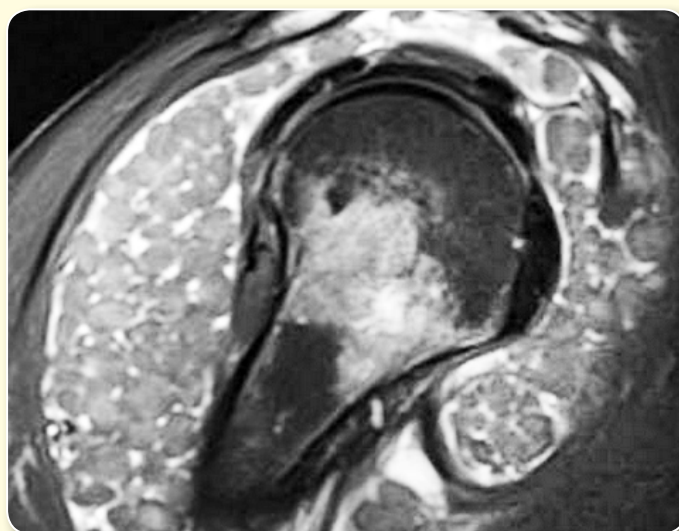

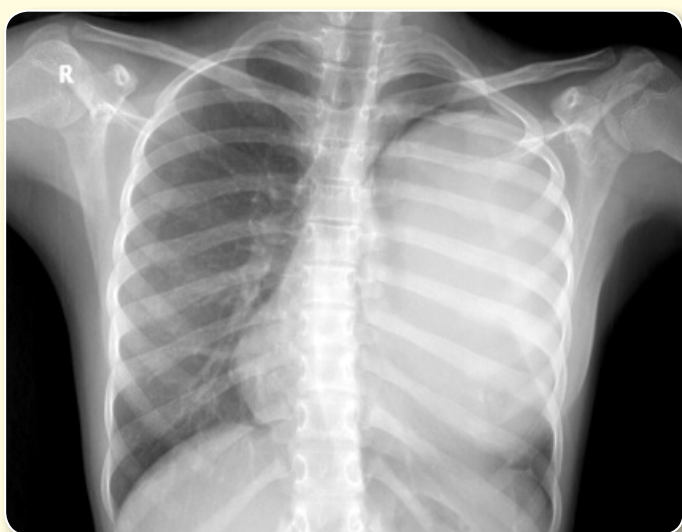
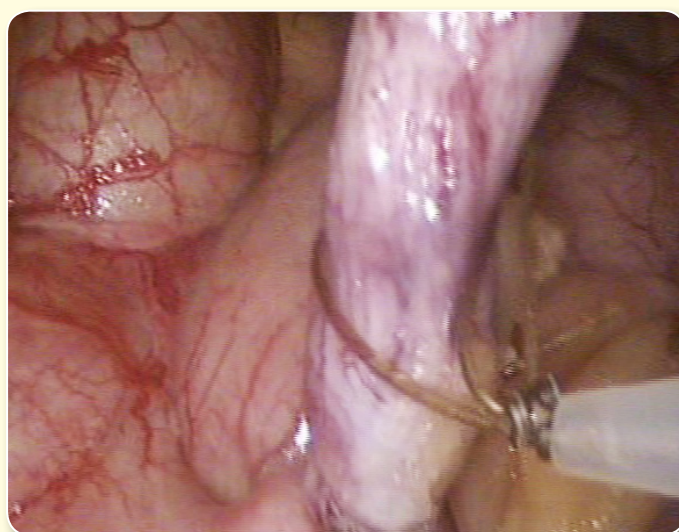
**49..** *Right vertical infra axillary thoracotomy....*



**53..** *Imaging of cartilaginous lesions of the synovium ....*



**72..** *Spontaneous rupture of giant hydatid cyst of lung into left bronchus....*



**77..** *Laparoscopic appendectomy in a patient of 32 weeks....*