Journal of Medical and Scientific Research

JMSR
www.jmsronline.com

Sunil S et al. J Med Sci Res. 2025; 13(3):308-310
DOI: http://dx.doi.org/10.17727/JMSR.2025/13-54

CASE REPORT OPEN ACCESS

Ultrasound-assisted neuraxial anaesthesia in a parturient with congenital kyphoscoliosis and prior spinal instrumentation: A case report

Sunil S[1], Nirenjen SM[1,*] and Venkatesh S[1]

[1]Department of Anesthesiology and Pain Medicine, Sri Ramachandra Institute of Higher Education and Research, Porur, Chennai - 600116, Tamil Nadu, India

Abstract

Pregnant patients with kyphoscoliotic deformities, particularly those of congenital origin, present unique anaesthetic challenges due to distorted vertebral anatomy, restrictive lung disease, and compromised cardiopulmonary reserve. Previous spinal surgery may obscure surface landmarks and alter interlaminar anatomy, making neuraxial blockade technically difficult. Nevertheless, with meticulous preoperative assessment, interdisciplinary planning, and the adjunctive use of ultrasonography, neuraxial anaesthesia remains a viable option. Preoperative ultrasound facilitates identification of intervertebral spaces, estimates the depth of the epidural space, and improves first-attempt success rates. Its integration into regional anaesthesia practice enhances both the safety and success of neuraxial blocks, reaffirming its value as a standard of care in high-risk obstetric patients with complex spinal deformities. In our case we see a G2L1 patient with congenital kyphoscoliosis with previous instrumentation came for elective LSCS.

Keywords: congenital kyphoscoliosis; caesarean section; neuraxial anaesthesia; obstetric anaesthesia

Introduction

Kyphoscoliosis is a complex spinal deformity characterized by the presence of both kyphotic and scoliotic curvatures. Anaesthetic management of such patients is particularly challenging, especially in the obstetric population. Both general and neuraxial anaesthesia pose unique difficulties due to restrictive lung disease, reduced pulmonary reserve, and distorted vertebral anatomy [1].

General anaesthesia carries risks of haemodynamic instability, rapid desaturation, difficult airway management, and aspiration, whereas neuraxial techniques may be technically difficult and less predictable due to altered surface landmarks and prior spinal instrumentation. Successful management of these high-risk cases requires meticulous preoperative assessment, multidisciplinary planning, and the use of adjuncts such as preprocedural ultrasonography to optimize the chances of a successful neuraxial block.

Case report

A 32-year-old gravida 2, para 1 woman with a known history of congenital kyphoscoliosis was admitted for elective lower segment caesarean section (LSCS) at 39 weeks of gestation. She weighed 70 kg. Routine laboratory investigations were within normal limits. On clinical examination, heart sounds were normal, and air entry was decreased in the right inframammary region. Airway assessment revealed Modified Mallampati class II with adequate mouth opening and normal neck extension. Examination of the spine demonstrated significant thoracolumbar kyphoscoliosis as seen in

***Corresponding author:** Dr. Nirenjen SM, Assistant professor, Department of Anaesthesiology and Pain Medicine, Sri Ramachandra Institute of Higher Education and Research, Porur, Chennai - 600116, Tamil Nadu, India. Email: niren7708@gmail.com

Received 18 April 2025; *Revised* 3 June 2025; *Accepted* 11 June 2025; *Published* 19 June 2025

Citation: Sunil S, Nirenjen SM, Venkatesh S. Ultrasound-assisted neuraxial anaesthesia in a parturient with congenital kyphoscoliosis and prior spinal instrumentation: A case report. J Med Sci Res. 2025; 13(3):308-310. DOI: http://dx.doi.org/10.17727/JMSR.2025/13-54

Copyright: © 2025 Sunil S et al. Published by KIMS Foundation and Research Center. This is an open-access article distributed under the terms of the Creative Commons Attribution License, which permits unrestricted use, distribution, and reproduction in any medium, provided the original author and source are credited.

figure 1. The patient had undergone posterior spinal stabilization with vertebral body tethering 10 years earlier. She had no neurological deficits.

Figure 1: Kyphoscoliotic spine of the patient.

After thorough counselling and obtaining informed consent, the patient was shifted to the operating theatre. Standard ASA monitors were attached, and baseline vital signs were recorded. Considering the presence of restrictive lung disease and the risks associated with general anaesthesia in parturients, regional anaesthesia was planned.

Preprocedural ultrasonography of the spine was performed in the sitting position using a low-frequency curvilinear probe. Both longitudinal paramedian and transverse scans were obtained to identify suitable intervertebral spaces. The L3–L4 interspace was marked, and a paramedian approach was chosen.

In the paramedian longitudinal plane, the transducer was placed approximately 2 cm lateral to the midline in a cephalocaudal orientation to identify lumbar interlaminar spaces. Transverse plane scanning was used to confirm the appropriate level by visualizing bilateral transverse processes in the same plane.

Using a 16G Tuohy needle, the epidural space was identified by loss of resistance to air, and an epidural catheter was threaded. Subsequently, a 25G Quincke spinal needle was introduced through the same space (Figure 2). Free flow of cerebrospinal fluid confirmed subarachnoid placement. A dose of 2.2 mL of 0.5% hyperbaric bupivacaine was administered intrathecally. The operating table was tilted 20° to the left to achieve a neutral position and reduce aortocaval compression.

Sensory block to T6 was achieved on the right side within 6 minutes and on the left side within 8 minutes. Following confirmation of a bilateral T6 block, surgery was initiated. The intraoperative course was uneventful, with stable haemodynamics and no need for epidural supplementation. A healthy infant was delivered with good Apgar scores.

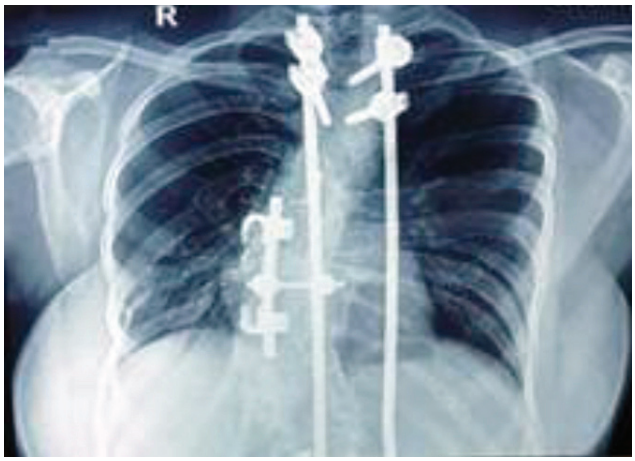

Figure 2: Previous x-ray image showing spinal instrumentation.

Postoperatively, the patient's recovery was uneventful, and she was discharged on postoperative day 3.

Discussion

Administering anaesthesia to parturients with congenital spinal deformities and prior corrective spinal surgery is particularly challenging, especially when neuraxial techniques are considered. In this case, regional anaesthesia was successfully performed under ultrasound guidance for an elective lower segment caesarean section (LSCS) in a patient with congenital thoracolumbar kyphoscoliosis and prior spinal instrumentation. With careful pre-procedural imaging, multidisciplinary planning, and a customised anaesthetic approach, neuraxial blocks can remain a safe and viable option even in patients with complex spinal anatomy.

Kyphoscoliosis causes significant alterations in spinal architecture, making neuraxial block placement technically challenging and rendering surface landmarks unreliable. Previous spinal instrumentation can distort the epidural space and alter cerebrospinal fluid dynamics, which may lead to failed or patchy blocks due to asymmetric spread of local anaesthetic [2]. Midline surgical scars and uncertainty about the extent of spinal fusion can also make blind techniques hazardous. Historically, these factors were considered relative contraindications to regional anaesthesia. However, increasing experience and improved imaging modalities have shown that, with proper planning, neuraxial techniques can be safely performed in such patients.

Ultrasonography allows for accurate identification of interlaminar spaces, estimation of epidural depth, and assessment of spinal instrumentation. In our patient, real-time ultrasound enabled precise localization of the L3–L4 interspace, facilitating safe and successful block placement. Evidence shows that spinal ultrasonography reduces the number of needle passes and increases first-attempt success rates in patients with difficult spinal anatomy [3]. Multiple case series have confirmed its role as a valuable pre-procedural assessment tool for patients with previous spinal abnormalities or surgeries [4].

In patients with scoliosis, the risk of unilateral or inadequate block is higher. The combined spinal–epidural (CSE) technique offers flexibility to address these challenges, as the epidural catheter allows for supplementation or extension of the block if needed [5]. Given the unpredictable intrathecal drug spread in patients with distorted spinal anatomy and cerebrospinal fluid asymmetry, a CSE approach provides better control over the level and duration of anaesthesia [6].

Another important factor influencing the choice of regional anaesthesia in this case was the patient's compromised pulmonary function. Kyphoscoliosis is associated with reduced lung volumes and chest wall compliance, leading to restrictive lung disease. Pregnancy further decreases functional residual capacity and increases oxygen consumption, which may significantly reduce respiratory reserve [7]. General anaesthesia in such patients carries additional risks, including rapid desaturation, difficult airway management due to airway oedema, and a higher risk of aspiration [8]. Hence, the benefits of avoiding general anaesthesia, when feasible, outweigh the risk of neuraxial block failure. As demonstrated in our case, functional lumbar spaces often remain accessible below the level of spinal instrumentation, making neuraxial anaesthesia possible. Prior spinal surgery alone should therefore not be considered an absolute contraindication.

Safe perioperative management of such cases relies on a multidisciplinary approach. Preoperative imaging, detailed respiratory assessment, and early involvement of obstetric, anaesthetic, and spine surgery teams are essential. Preparation for potential regional block failure and difficult airway management is critical, including the availability of advanced airway equipment and backup plans.

Conclusion

In conclusion, this case highlights that with careful preoperative assessment, appropriate imaging, and meticulous technique, regional anaesthesia can be a safe and effective option for obstetric patients with complex spinal pathology. The use of ultrasound guidance, consideration of pulmonary function, and multidisciplinary planning are key to achieving successful outcomes. This case supports the growing evidence that, when carefully tailored, ultrasound-guided neuraxial anaesthesia may be preferable to general anaesthesia in high-risk parturients with spinal deformities and prior spinal instrumentation.

Acknowledgements

Obstetrics surgical team of Sri Ramachandra Institute of Higher Education and Research.

Conflicts of interest

Authors declare no conflicts of interest.

References

[1] Bansal N, Gupta S. Anaesthetic management of a parturient with severe kyphoscoliosis. Kathmandu Univ Med J (KUMJ). 2008; 6:379–382.
[2] Hebl JR, Horlocker TT, Kopp SL. Neuraxial block in patients with preexisting central nervous system disorders. Anesth Analg. 2006; 103:223–228.
[3] Grau T, Leipold RW, Conradi R, Martin E, Motsch J. Efficacy of ultrasound imaging in obstetric epidural anaesthesia. J Clin Anesth. 2002; 14:169–175.
[4] Karmakar MK, Li X, Ho AM, Kwok WH, Chui PT. Real–time ultrasound–guided paramedian epidural access: evaluation of a novel in–plane technique. Br J Anaesth. 2009; 102:845–854.
[5] Buxbaum JL. Combined spinal–epidural for labor analgesia. Curr Opin Anaesthesiol. 1999; 12:295–298.
[6] Reynolds F. Damage to the conus medullaris following spinal anaesthesia. Anaesthesia. 2001; 56:238–247.
[7] Caro CG, Dubois AB. Pulmonary function in kyphoscoliosis. Thorax. 1961; 16:282–290.
[8] Rocke DA, Murray WB, Rout CC, Gouws E. Relative risk analysis of factors associated with difficult intubation in obstetric anaesthesia. Anesthesiology. 1992; 77:67–73.
[9] Sadeghi A, Patel R, Carvalho JCA. Ultrasound–facilitated neuraxial anaesthesia in obstetrics. BJA Educ. 2021; 21:369–375.