

## Adenocarcinoma arising in a small bowel duplication cyst

Kashif M Mohiuddin<sup>1</sup>, Satish Rao I<sup>1\*</sup> and Daga Sachin V<sup>1</sup>

<sup>1</sup>Department of Pathology, Krishna Institute of Medical Sciences, Minister Road, Secunderabad-500003, Telangana, India

<sup>2</sup>Department of Surgical Gastroenterology, Krishna Institute of Medical Sciences, Minister Road, Secunderabad-500003, Telangana, India

### Abstract

**Background:** Enteric duplication cysts are uncommon congenital anomalies containing a normal gastrointestinal mucosa and smooth muscle layer that can occur anywhere throughout the digestive tract. Duplication cysts have the potential for neoplastic transformation.

**Case report:** This report describes a case of adenocarcinoma arising from a duplication cyst of small bowel, with invasion and breach of cyst wall, in a 40-year-old gentleman. A cystic lesion was found in the small bowel mesentery which had a well circumscribed smooth muscle layer beneath the layer of ulceration consisting of lymphocyte collection, macrophages and degenerating epithelial cells. A well differentiated adenocarcinoma was found within the wall of duplication cyst, invading its serosa and metastasis to mesenteric lymph node. The adjacent bowel segment submitted was having no lesion suggesting that the carcinoma had originated from the duplication cyst.

**Conclusion:** It is difficult to diagnose a malignancy arising in a duplication cyst radiologically therefore a duplication cyst should be surgically removed completely as it carries an unpredictable risk of malignant transformation even if it is asymptomatic or apparently benign.

**Keywords:** small intestine duplication cyst; adenocarcinoma; enteric duplication cyst

**\*Corresponding author:** Dr. I. Satish Rao, Department of Pathology, Krishna Institute of Medical Sciences, Minister Road, Secunderabad-500003, Telangana, India. Tel.: 9866232280; Email: [isatishrao@gmail.com](mailto:isatishrao@gmail.com)

Received 29 December 2017; Revised 17 February 2018; Accepted 01 March 2018; Published 16 March 2018

**Citation:** Kashif MM, Satishrao I, Sachin DV. Adenocarcinoma arising in a small bowel duplication cyst. J Med Sci Res. 2018; 6(2):59-62. DOI: <http://dx.doi.org/10.17727/JMSR.2018/6-10>

**Copyright:** © 2018 Kashif MM et al. Published by KIMS Foundation and Research Center. This is an open-access article distributed under the terms of the Creative Commons Attribution License, which permits unrestricted use, distribution, and reproduction in any medium, provided the original author and source are credited.

### Introduction

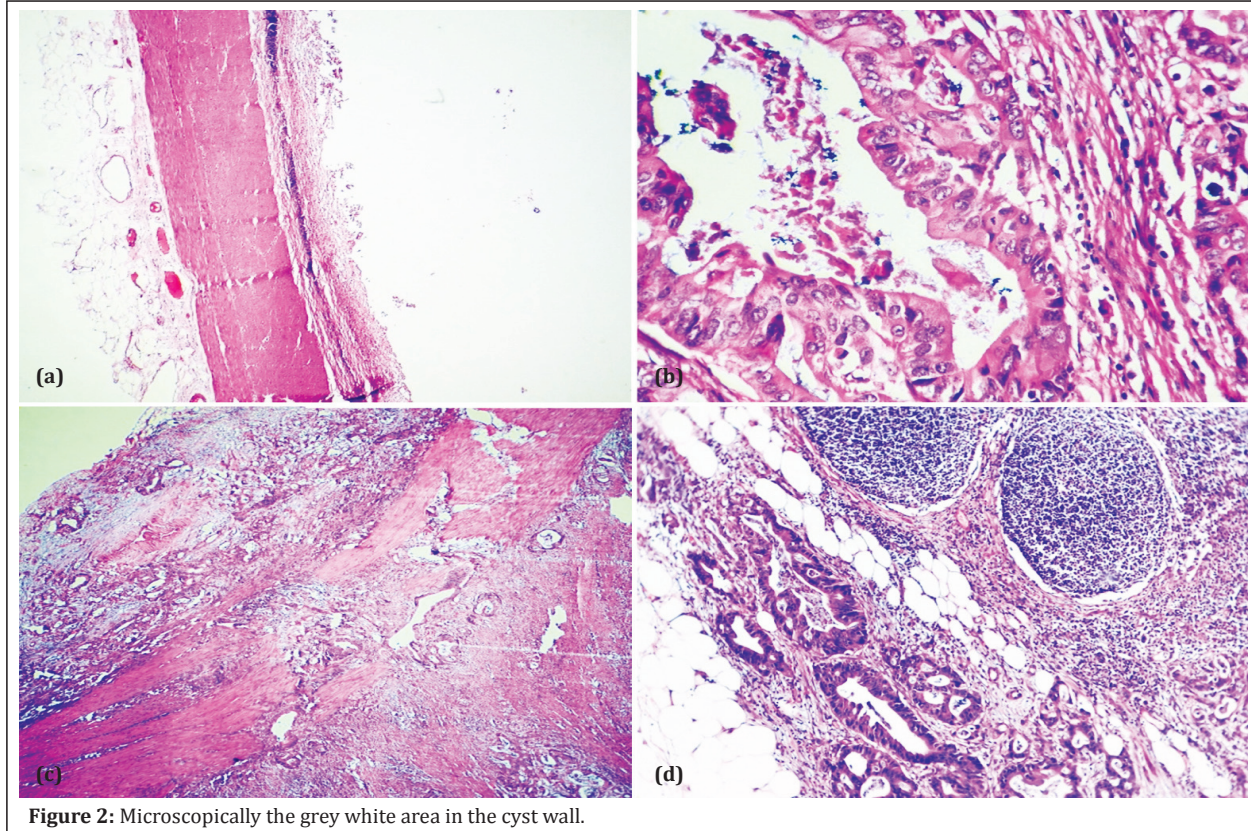
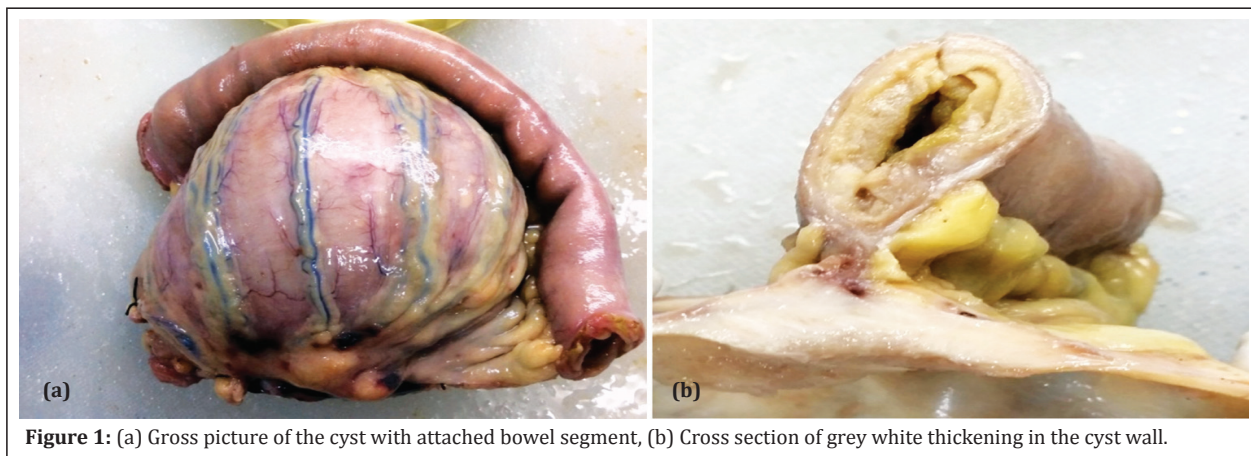
Ladd WE first characterized the term 'alimentary duplication cyst' and described them as congenital malformations which involve the mesenteric side of the associated alimentary tract which share a common blood supply with the native bowel [1]. They are diagnosed commonly in early life and rarely in adults [2]. The prevalence is between 1:4500–1:10000 [3]. Malignant change occurs rarely in duplication cyst [4]. We present a case report of an adenocarcinoma arising in a coincidentally found cystic duplication of the small bowel.

### Case report

A 40-year-old male presented with abdominal pain.

High-dose contrast-enhanced computed tomography (CECT) showed a fluid filled mesenteric mass in the abdomen. Patient was operated and per operatively there was a cystic mass arising from the mesentery of the small bowel. It was sent for histopathology examination. Grossly the specimen was of grey white thick walled cyst containing brown fluid of size 7 × 6 × 5 cm attached to the intestinal segment of size 13 × 2.5 cm ( Figure 1a). There was a thickened grey white area of size 2 × 2 × 1 cm (Figure 1b), in the cyst wall near its attachment to the bowel segment. Microscopically the cyst wall had a well circumscribed

smooth muscle layer, which was beneath layer of ulceration consisting of collection of lymphocytes, macrophages and degenerating epithelial cells (Figure 2a). Sections from the grey white area in the cyst wall showed infiltrating irregular neoplastic glands lined by cells showing high N/C ratio with round to oval pleomorphic nuclei and eosinophilic cytoplasm (Figure 2b). There was transmural extension of the neoplastic glands in to the peri cystic soft tissue (Figure 2c) and involvement of two lymph nodes out of 6 lymph nodes dissected with perinodal tumor extension (Figure 2d).



## Discussion

Enteric duplications (EDs) occur anywhere along the gastrointestinal tract [2]. The majority of EDs are small bowel duplications [5-8]. Fitz first used the term intestinal duplications cysts [9] but was later popularized by Ladd in the 1930s as enteric duplications (EDs). Ladd has described EDs as congenital malformations which involve the mesenteric side of the associated alimentary tract and share a common blood supply with the native bowel [1]. The etiology of ED still remains unknown. Many theories have been postulated such as an abnormal recanalization after the solid epithelial stage of embryonic bowel development [10]. Other theories consider persisting embryologic diverticula or 'aborted Gemini', partial twinning, and split notochord theory. However the most accepted theory is the 'intrauterine vascular accident theory' [11].

EDs are usually diagnosed in first year of life and they are rare in adulthood. Commonly patients present vague symptoms which mimic other more common pathologies such as volvulus, appendicitis, intussusceptions, pelvic abscess, diverticulitis, achalasia, and Hirschsprung's disease [12]. Many authors have reported variable clinical picture depending on location, size and other factors like presence of ectopic mucosa, communication with adjacent bowel, or inflammation [13]. Infants and neonates present with abdominal pain, nausea, vomiting, bleeding, abdominal distension,

abdominal mass, obstruction, intussusceptions. Some duplication cysts may remain asymptomatic till adulthood. Diagnosis is usually done using imaging modalities such as barium studies, USG, CT scans or MRI.

CT scans are more useful in demonstrating the precise anatomical relationship between the cysts and surrounding structures. These cysts can manifest as smooth, rounded, fluid filled cysts or tubular structure with thin slightly enhancing wall on CT scan.

However, all these modalities allow us only to suspect the presence of an abnormal lesion but ruling out a malignant change is difficult and diagnostic confirmation is possible only after resection. For the diagnosis of an enteric duplication cyst, three essential histological characteristics are: a well-developed smooth muscle coat; mucosal lining found within some portion of the alimentary tract; contiguity to any segment of the alimentary tract.

Carcinomas arising in duplication cysts is a rare complication and only few cases have been reported in literature including gastrointestinal stromal tumor, carcinoid tumor, squamous cell carcinomas, and adenocarcinomas (Table 1). In the literature Small bowel duplications are frequently the site of malignancy, followed by colonic and rectal duplications [12]. Adenocarcinomas are the most frequently encountered neoplasm arising from the small bowel.

**Table 1:** Carcinomas arising in duplication cysts is a rare complication (Literature).

<i>Case reports</i>	<i>Age</i>	<i>Sex</i>	<i>Location</i>	<i>Type of carcinoma</i>
Amadeu P. A. Pimenta et al.,	61	Male	Esophagus	Squamous cell carcinoma
Kuraoka K et al.,	40	Male	Stomach	Well differentiated adenocarcinoma
Kusunoki N et al.,	73	Male	Jejunum	Adenocarcinoma
Barussaud ML et al.,	67	Male	stomach	Mixed adenocarcinoma and squamous cell carcinoma
Kim TH et al.,	40	Male	Jejunum	Papillary adenocarcinoma
Devos B et al.,	34	Female	Ileum	Adenocarcinoma
De Tullio D	88	Female	Ileum	Moderately differentiated adenocarcinoma
Thomas Micolonghi	54	Male	Ileum	Gastric type adenocarcinoma
Adair HM	65	Male	Small bowel	Squamous cell carcinoma
Fernandez DC	71	Male	Stomach	Gastro intestinal stromal tumor
Ribaux C	64	Male	Ileum	adenocarcinoma
Hata H	34	Female	Duodenum	Carcinoid tumor
George A. Radich	39	Female	Small bowel	Papillary adenocarcinoma
De Tullio D	88	Female	Ileum	Adenocarcinoma

Complete removal of the cyst is the treatment of choice to avoid the risk of possible complications such as obstruction, torsion, perforation, hemorrhage, and malignancy [14, 15].

In the present case, the adenocarcinoma extended and breached the serosa covering the cyst and metastasized to mesenteric lymph nodes. There was neither adenocarcinoma *in situ* nor precancerous lesion, such as epithelial dysplasia, in the bowel specimen attached to the cyst.

The tumors are usually diagnosed at advanced stage with metastasis as in the present case due to non specific symptoms and rare presentation. Malignancies of small bowel duplications tend to have high rate of lymph node metastasis due to which curative resections are difficult [16]. The prognosis following surgery for these malignant duplication cysts is variable. This depends on the extent of tumor progression at presentation.

## Conclusion

Even with modern methods of imaging, the diagnosis of malignant transformation of the cyst can be difficult; therefore duplication cysts should be surgically removed even for asymptomatic or apparently benign cyst.

## Acknowledgements

Department of pathology and Surgical Gastroenterology, KIMS hospitals for their support.

## Conflicts of interest

Authors declare no conflicts of interest.

## References

- [1] Ladd WE, Gross RE. Surgical treatment of duplications of the alimentary tract. *Surg Gynecol Obstet.* 1940; 70:295–307.
- [2] Johnson JA, Poole GV. Ileal duplications in adults. Presentation and treatment. *Arch Surg.* 1994; 129(6):659–661.
- [3] Macpherson RI. Gastrointestinal tract duplications: Clinical, pathologic, etiologic, and radiologic considerations. *Radiographics.* 1993; 13(5):1063–1080.
- [4] Orr MM, Edwards AJ. Neoplastic change in duplications of the alimentary tract. *Br J Surg.* 1975; 62(4):269–274.
- [5] Schalamon J, Schleef J, Höllwarth ME. Experience with gastro-intestinal duplications in childhood. *Langenbecks Arch Surg.* 2000; 385(6):402–405.
- [6] Karnak I, Ocal T, Senocak ME, Tanyel FC, Büyükpamukcu N. Alimentary duplications in children: Report of 26 years' experience. *Turk J Pediatr.* 2000; 42(2):118–125.
- [7] Kuo HC, Lee HC, Shin CH, Sheu JC, Chang PY, et al. Clinical spectrum of alimentary tract duplication in children. *Acta Paediatr Taiwan.* 2004; 45(2):85–88.
- [8] Olajide ARL, Yisau A, Abdulraseed NA, Kashim IO, Olaniyi AJ, et al. Gastrointestinal duplications: Experience in seven children and a review of the literature. *Saudi J Gastroenterol.* 2010; 16(2):105–109.
- [9] Fitz RH. Persistent omphalomesenteric remains: Their importance in the causation of intestinal duplication, cyst formation and obstruction. *Am J Med Sci.* 1884; 88:30–57.
- [10] Bremer JL. Diverticula and duplications of the intestinal tract. *Arch Pathol.* 1944; 38:132–140.
- [11] Favara BE, Franciosi RA, Akers DR. Enteric duplications. Thirty-seven cases: A vascular theory of pathogenesis. *Am J Dis Child.* 1971; 122(6):501–506.
- [12] Blank G, Königsrainer A, Sipos B, Ladurner R. Adenocarcinoma arising in a cystic duplication of the small bowel: Case report and review of literature. *World J Surg Oncol.* 2012; 10:55.
- [13] Cavar S, Bogovic M, Leutic T, Antabak A, Batinica S. Intestinal duplications – experience in 6 cases. *Eur Surg Res.* 2006; 38(3):329–332.
- [14] Horne G, Ming-Lum C, Kirkpatrick AW, Parker RL. High-grade neuroendocrine carcinoma arising in a gastric duplication cyst: a case report with literature review. *Int J Surg Pathol.* 2007; 15(2):187–191.
- [15] Mardi K, Kaushal V, Gupta S. Foregut duplication cysts of stomach masquerading as leiomyoma. *Indian J Pathol Microbiol.* 2010; 53(1):160–161.
- [16] Kusunoki N, Shimada Y, Fukumoto S, Iwatani Y, Ohshima T, et al. Adenocarcinoma arising in a tubular duplication of the jejunum. *J Gastroenterol.* 2003; 38(8):781–785.