

A rare case of non-tuberculous mastitis

Latha Sarma^{1*}, Asmath Qureshi¹, Kapil Alias Mohit Chilana¹ and Nandan Putti¹

¹Department of Pulmonology, Krishna Institute of Medical Sciences, Minister Road, Secunderabad-500003, Telangana, India

Abstract

A 15-year-old girl presented with left breast lump with purulent discharge. During the last three months she lost 4 kg weight. There was evening rise of temperature which was not associated with joint pains or chills. She had received three courses of antibiotics earlier in the other healthcare center, with no response. Ultrasound scan showed multiple cutaneous sinuses and FNA report findings were suggestive of chronic granulomatous mastitis. As the patient was not responding to multiple antibiotics courses, HRZE (Anti Tubercular Treatment, ATT) was started. But after three months of ATT she developed multiple sinus tracts filled with fluid and with superficial ulcerations, which was aspirated, sent for analysis and oral Moxifloxacin 400 mg was added. DNA based line probe assay detected Non Tuberculous mycobacterium (NTM) and was referred for NTM species identification. Molecular genetics assay identified *Mycobacterium chelonae/ Mycobacterium immunogenum* species and HRZE regimen was stopped. Patient was started on oral clarithromycin, linezolid according to sensitivity report. She responded well and repeat ultrasound scan showed significant resolution of the sinus and there was no discharge. NTM should be considered for breast infections that recur despite standard antibiotic therapy or ATT.

Keywords: nontuberculous mastitis; anti tubercular therapy; antibiotics

***Corresponding author:** Dr. Latha Sarma, Critical respiratory & Sleep specialist, Department of Pulmonology, Krishna Institute of Medical Sciences, Minister Road, Secunderabad-500003, Telangana, India. Email: dr.lathasarma@gmail.com

Received 05 April 2016; Revised 29 May 2015; Accepted 16 June 2015; Published 28 June 2016

Citation: Sarma L, Qureshi A, Chilana KAM, Putti N. A rare case of non-tuberculous mastitis. J Med Sci Res. 2016; 4(3):115-117. DOI: <http://dx.doi.org/10.17727/JMSR.2016/4-028>

Copyright: © 2016 Sarma L, et al. Published by KIMS Foundation and Research Center. This is an open-access article distributed under the terms of the Creative Commons Attribution License, which permits unrestricted use, distribution, and reproduction in any medium, provided the original author and source are credited.

Case presentation

15-year-old girl presented with left breast lump with purulent discharge, 4 kg weight loss and evening rise of temperature since three months which was not associated with joint pains or chills. She had received three courses of antibiotics with no response and was referred to KIMS hospital, Secunderabad. Ultrasound scan showed multiple cutaneous sinuses in left breast with small subcutaneous collection. Her previous fine-needle aspiration (FNA) report findings were suggestive of chronic granulomatous mastitis and no organisms were identified. In the hospital aspiration of pus was suggested, but was not successful. In view of prodromal symptoms, granulomatous mastitis and multiple discharging sinuses, positive Mantoux test, increased erythrocyte sedimentation rate (ESR), not

responding to multiple antibiotics courses, HRZE (Anti Tubercular Treatment, ATT) was started.

Observation

In the next 3 months the discharge reduced and fever episodes subsided. But after three months of ATT she developed multiple sinus tracts filled with fluid and with superficial ulcerations, which was aspirated, sent for analysis and oral moxifloxacin 400 mg was added. Cytology (Figures 1 and 2) revealed abundant necrotic material, few degenerate epithelial cells, negative for malignant cells, Ziehl–Neelsen stain was negative for Acid-fast bacilli, but Mycobacterium tuberculosis DNA (MTB-DNA) PCR was positive. In view of these reports, ATT was continued and TB-culture report was awaited. After two weeks of incubation AFB was grown in culture. DNA based line probe assay detected non tuberculous mycobacterium (NTM) and was referred for NTM species identification.

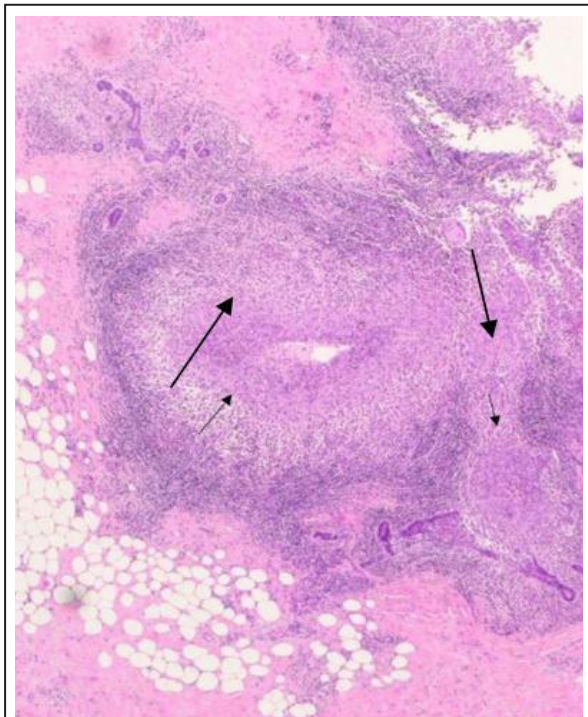


Figure 1: Low power field of an excision biopsy of the breast mass showing a mixed inflammatory cell infiltrate with suppurative granulomas.

Molecular genetics assay for identification of Mycobacterial species showed *M.chelonae*/*M.immunogenum* species, which were sensitive to clarithromycin, linezolid, imipenem, amikacin and resistant to isoniazid, rifampicin, ethambutol,

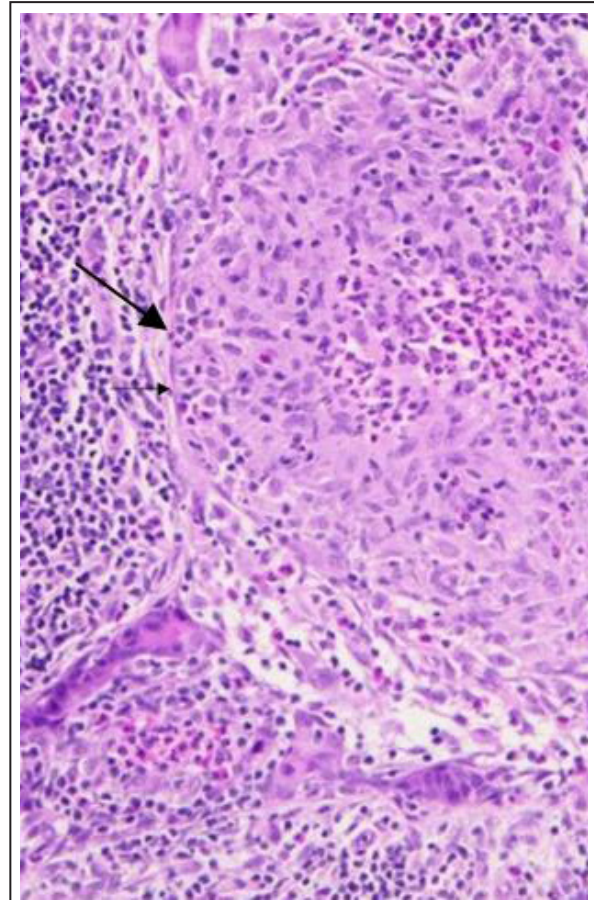


Figure 2: High power field showing suppurative granuloma including giant cells. The granulomatous inflammation is centered on ducts and lobules.

streptomycin, kanamycin, levofloxacin, ciprofloxacin, cotrimoxazole, doxycycline.

HRZE regimen was stopped and patient was started on oral clarithromycin, linezolid and surgical advice was taken for possible drainage of the collection and surgeon advised to continue medical management under close follow up. She responded well. Repeat ultrasound scan chest done after two months of above treatment and there was significant resolution of the sinus and there was no discharge.

Discussion

Rarely, NTM organisms can cause breast infections [1, 2]. The nontuberculous Mycobacteria (NTM) infections may be acute, subacute, or late-onset. Interestingly, previous reports have typically described bilateral NTM breast infections. The most common organisms found in these infections included *Mycobacterium fortuitum*, *Mycobacterium Avium*, *Mycobacterium abscessus*, and less commonly,

Mycobacterium chelonae. NTM should be considered as a source of infection when standard bacterial culture results are negative.

Once an NTM organism is isolated by culture, the infection should be treated with targeted combined antibiotic therapy. The most commonly reported organism of skin and soft tissue disease in NTM infections is *Mycobacterium fortuitum*. The majority reported an association between the onset of infection and breast implants or reconstructive surgery [3-6]. For postoperative wound infections, the removal of implants or infected foreign bodies is required. Patients treated according to in vitro susceptibilities of isolated colonies have shown good results in a previous study. A primary panel of drugs for susceptibility testing may include amikacin, cefotaxim, ciprofloxacin, clarithromycin, doxycycline, imipenem, and a sulphonamide [7]. However very few studies have reported NTM breast infections not associated with implants [8].

Conclusion

In extrapulmonary tuberculosis, as in this case of tuberculous mastitis, initial histopathological and microbiological samples maybe inadequate and initial reports may not indicate exact diagnosis. Follow up along with repeated cultures and biopsies are essential, especially when there is no clinical improvement with empirical ATT. This case is unique as it involved young girl, who had granulomatous mastitis. Though ATT was started, there was no significant resolution; it was pursued by repeating cultures. The patient was not immunocompromised and had no history of breast surgery, or implant insertion. Therefore, the exact cause of NTM infection could not be determined initially. DNA based line probe assays detected NTM species identification was done by molecular genetic assay. It showed *Mycobacterium chelonae*, *Mycobacterium immunogenum* sensitivity for antibiotics was tested accordingly treatment was started with clarithromycin and linezolid. The patient responded well. It is concluded that although it is difficult to differentiate from other causes due to nonspecific imaging findings, NTM should be considered for breast infections that recur despite standard antibiotic therapy or ATT.

Acknowledgements

Department of Pathology, Krishna Institute of Medical Sciences (KIMS), Secunderabad-500003, Telangana, India.

Conflicts of interest

Authors declare no conflicts of interest.

References

- [1] Chirra A. Nontuberculous mycobacterium infection of the breast. Proceedings of UCLA Healthcare.
- [2] Macadam SA, Mehling BM, Fanning A, Dufton JA, Kowalewska-Grochowska KT, et al. Nontuberculous mycobacterial breast implant infections. *Plast Reconstr Surg*. 2007; 119(1):337-344.
- [3] Coney PM, Thrush S. Cutaneous *Mycobacterium fortuitum* complicating breast reconstruction. *J Plast Reconstr Aesthet Surg*. 2007; 60(10):1162-1163.
- [4] Vinh DC, Rendina A, Turner R, Embil JM. Breast implant infection with *Mycobacterium fortuitum* group: Report of case and review. *J Infect*. 2006; 52(3):e63-e67.
- [5] Rimmer J, Hamilton S, Gault D. Recurrent mycobacterial breast abscesses complicating reconstruction. *Br J Plast Surg*. 2004; 57(7):676-678.
- [6] Haiavy J, Tobin H. *Mycobacterium fortuitum* infection in prosthetic breast implants. *Plast Reconstr Surg*. 2002; 109(6):2124-2128.
- [7] Diagnosis and treatment of disease caused by nontuberculous mycobacteria. This official statement of the American Thoracic Society was approved by the board of directors. 1997. *Am J Respir Crit Care Med*. 1997; 156(2 Pt 2):S1-S25.
- [8] Betal D, Macneill FA. Chronic breast abscess due to *Mycobacterium fortuitum*: a case report. *J Med Case Rep*. 2011; 5:188.